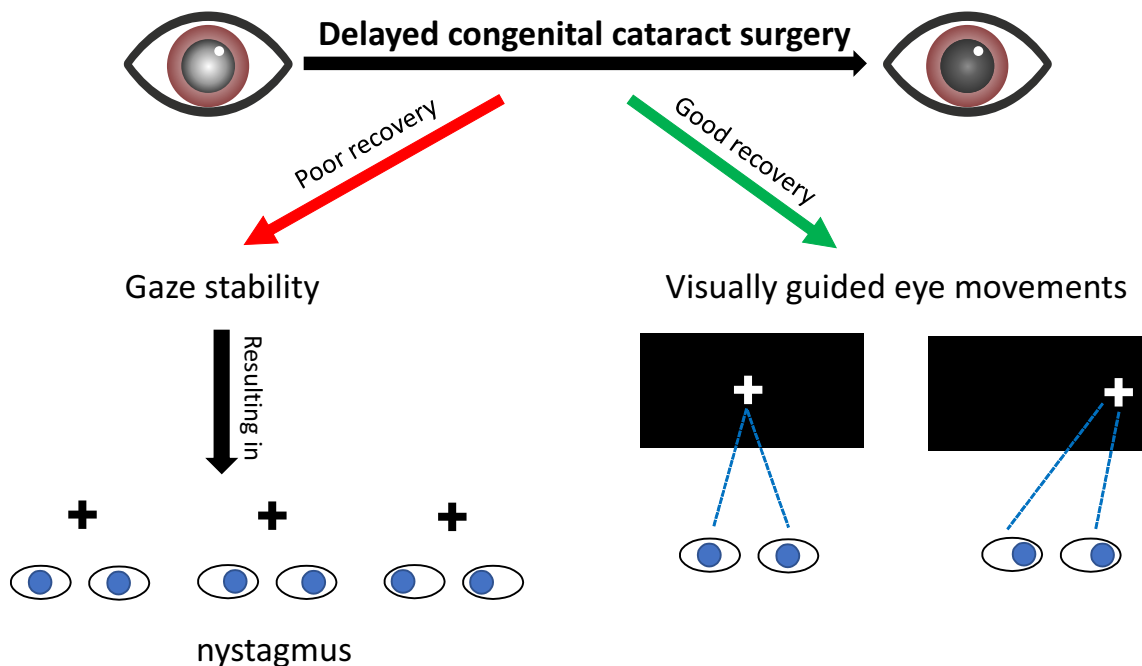


Indo-German Lab of LVPEI

Successful visually guided eye movements after delayed bilateral congenital cataract surgery

Paul Zerr, José P. Ossandón, Idris Shareef, Stefan Van der Stigchel,
Ramesh Kekunnaya, and Brigitte Röder



Delayed treatment for bilateral congenital cataracts leads to gaze instability (manifesting as Nystagmus) but does not prevent the development of visually guided eye movements.